

A silhouette of a person's head and torso is on the left. From their hand, a series of concentric, wavy lines radiate outwards, representing sound waves. The background is white with a grey rectangular area on the right containing the title. A red diagonal stripe is on the far right.

Sound Touch Elastography (STE) For Chronic Liver Disease (CLD): Guidelines & Case Studies

Pavlos S. Zoumpoulis MD, PhD
Kendy C. C. Ng BSc, RDMS, RDCS, RVT, MBA

Introduction

This White Paper provides clinicians with an easy-to-follow guide on both why and how to integrate STE Real Time Shear Wave Elastography (SWE) imaging into their liver Ultrasound examination. STE/SWE is a form of non-invasive evaluation of liver fibrosis staging, progression, prognosis and follow-up with good sensitivity and reproducibility.

As recommended and advocated by the EFSUMB and WFUMB practice Guidelines on liver SWE, proper training in performing SWE imaging is vital for better accuracy and reproducibility, as well as for limiting intra- and inter-observer variability.

The illustrated clinical cases in this paper are performed on Mindray Resona 7, with Single Crystal curved probe by the team of expert Radiologists of the Echomed Imaging Center, Athens Greece.

GUIDELINES: The EFSUMB and WFUMB Liver Elastography Guidelines must be taken into account for extended descriptions of the Physics and Technology applied in different types of Strain and SWE in the LIVER and for a detailed glossary of all Elastography-related terms.

TRAINING: The length of the learning curve depends on the number of patients with Chronic Liver Disease (CLD) performed under active supervision of an experienced Resona 7 user.

Seek training: Ask your experienced application specialist and/or colleague, trained in Liver STE/SWE, to show the crucial steps and system adjustments before starting performing STE/SWE on patients.

The following scanning protocol consists of the recommended steps for any clinician to perform in order to achieve reliable and reproducible Liver STE/SWE and avoid pitfalls and artifacts.

Liver STE/SWE Step by Step

- ❖ **Fasting:** Patient fasting and resting for 3–4 hours prior to the Shear Wave Elastography study is recommended.
- ❖ **B-Mode/Intercostal space:** Following the WFUMB and EFSUMB guidelines, use the intercostal approach with the patient in the supine position and with the right arm raised above the head to increase the width of the intercostal space and scan the liver (**Fig. 1**)
- ❖ When necessary the B-Mode exam should be extended to the Left Liver Lobe (LLL) using the convex SC5-1U or a Linear probe (L9-3U), if it is available, in order to visualize micro- or macro-lobulations on the anterior or ventral border of the Liver. Visualization of such lobulations is indicative of cirrhosis. Always obtain, firstly, the best possible B-mode image quality in real-time, because a quality Shear Wave Elastography application depends on the quality of the B-Mode image which should show the liver capsule as a white line without the rib's or lung's shadowing in the liver parenchyma.
- ❖ **Stiffness vs. Fibrosis:** During the B-Mode scan, examine the Inferior Vena Cava (IVC), Hepatic Veins (HVs), Portal Vein (PV) and Bile Ducts. Compression from dilated PV, IVC and HVs, Intrahepatic Bile Ducts or other causes that augment the endo-peritoneal pressure (ascites, pre-term pregnancy), may influence liver stiffness. One can easily avoid these pitfalls by using the B-Mode imaging. STE/SWE measures Liver stiffness, not the Liver's fibrotic content.

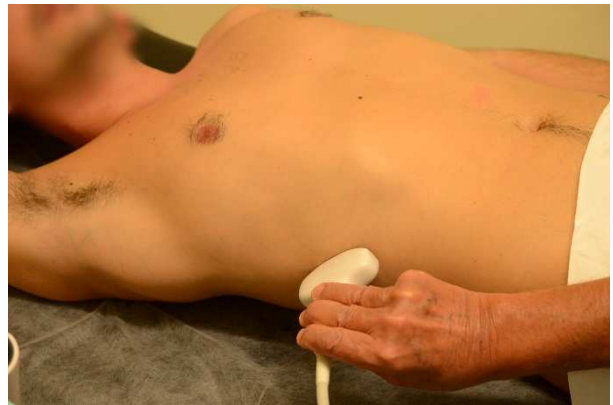

Fig. 1 Patient/Probe position for approaching the liver

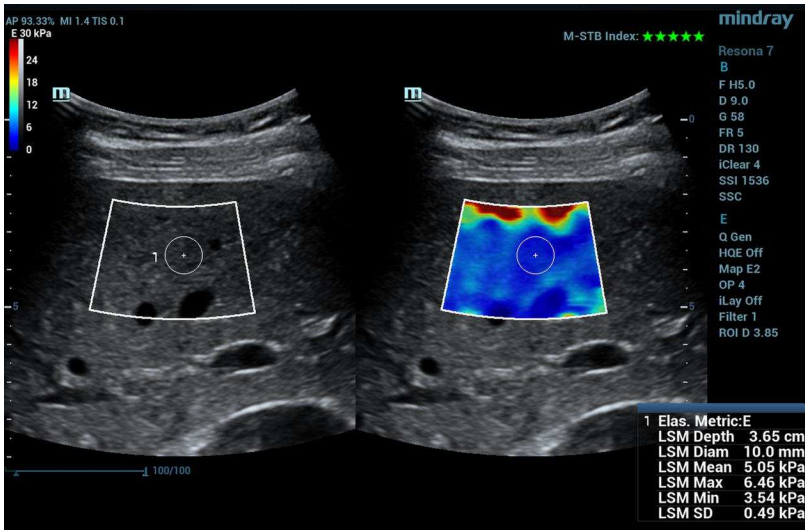


Fig. 2 “Red Color” artifact induced by excessive probe pressure may affect the stiffness quantification value in kPa and should not be used for stiffness measurement

❖ **Probe and Region of Interest (ROI) placement:**

The probe and the patient’s skin should form a 90° angle. Place the STE ROI box in the center of the B-mode image in a homogeneous area of the liver parenchyma, avoiding ligaments, vessels and bile ducts.

❖ **Probe / hand stability, liver immobility:**

Hold the probe steadily, while asking the patient to take a normal small breath and hold his/her breath for a few seconds at mid expiration. Then place the ROI at the center of the image. Main reason for doing so is to have the liver in front of the intercostal space that you have placed the probe on.

❖ **STE/SWE activation:**

When the patient holds and stops breathing, activate the Elastogram function on the Touch Screen STE key and observe both the B-Mode and the STE/SWE images, displayed side by side.

- ❖ **Avoiding artifacts:** To avoid reverberation artifacts, always position the upper edge of the sampling box (ROI) at 1 to 2 centimeters below the liver capsule and, if possible, avoid including any large or small vessels. Perform a “stability test” on the B-Mode image without excessive probe pressure. Excessive probe pressure or any vessel included in the ROI will cause the appearance of red artifacts (Fig.2).
- ❖ **Reliability Indicators:** The best possible frame of the STE image is indicated by both the 5 Green Stars Motion Stability Index (Fig. 3) and the, full of green color, RLB Map (Fig. 4). Using both reliability indicators assures better reproducibility and better inter-/intra-observer agreement of the STE/SWE measurements.
- ❖ **STE Cine loop:** Wait for the system to generate consecutive frames for 3-5 seconds and capture sequential STE images in a cine loop; use the trackball to choose the appropriate frames for performing STE measurements in accordance with the reliability indicators.

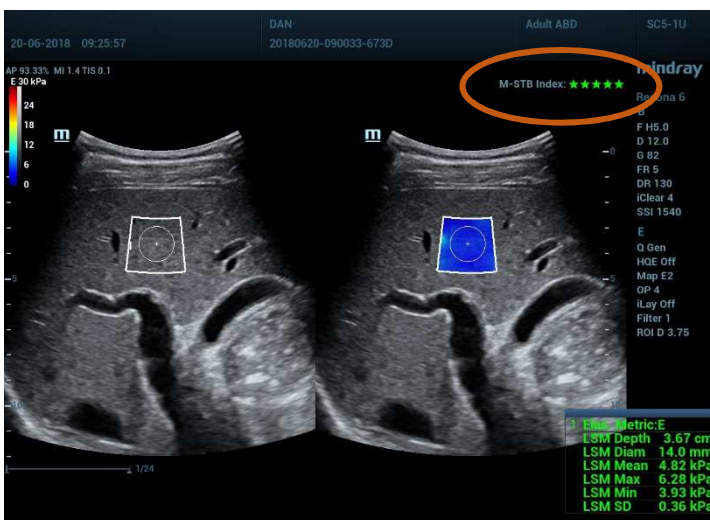


Fig. 3 The Motion Stability Index (“Green Stars”) indicates a high stability of consecutive frames which shows a high reliability without movement artifacts

❖ **Measurement:**

Use the measurement button to place the circular measurement area within the ROI box in the homogenous SWE color area (Fig. 5). For better accuracy, it is recommended to perform only one measurement for each acquisition either in m/s (speed of the Shear Waves) or kPa (stiffness value derived from the speed of the shear wave by using the Young modulus).

❖ **Circular measurement area:**

A ROI up to 1-1.5 cm in size is a good choice to yield better sensitivity and specificity to qualitatively assess the stiffness of the targeted liver parenchyma area. It is recommended to use a smaller circular measurement area to avoid artifacts that may degrade the quality of the Elastography measurement.

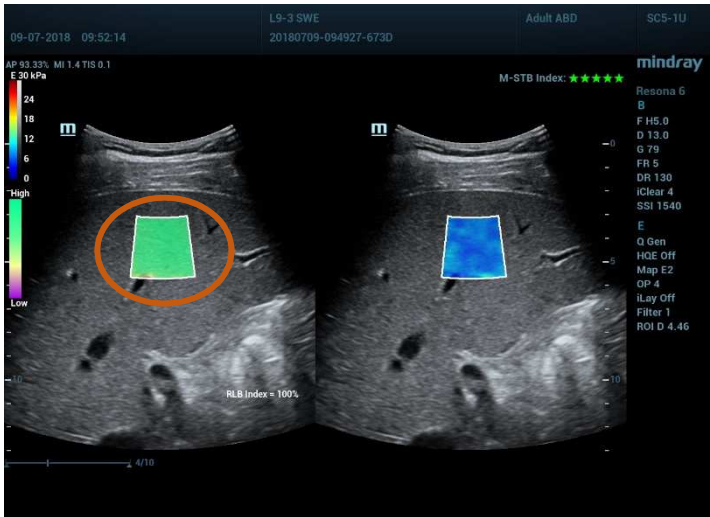


Fig. 4 Green RLB Map Reliability Index shows signal homogeneity in the selected STE Box indicating areas to avoid (vessels, artifacts) when placing the circular measurement

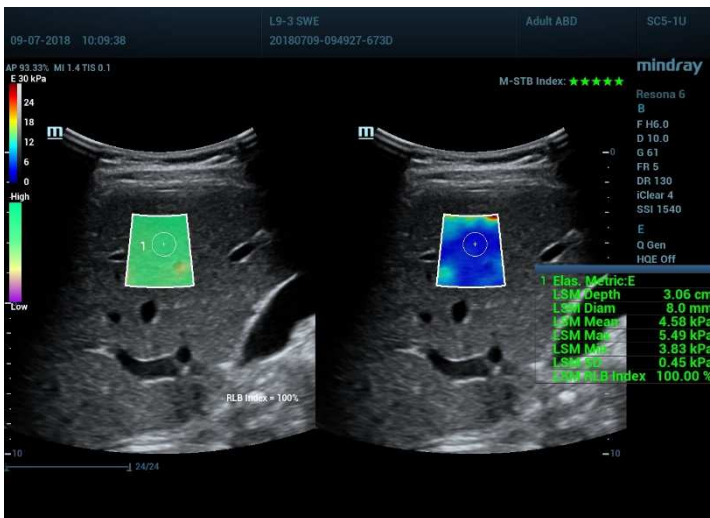


Fig. 5 Assessment of liver stiffness with STE. The 1cm diameter measurement box is used here as an example. The mean, the max and min values (kPa) and SD are displayed on the image. The depth of the measurement and size of the measurement box are also displayed.

Clinical Pitfalls

1. Fibrosis distribution: With the emergence of SWE and MRI Elastography we are now aware that during the long run of CLD, fibrotic tissue generation is not homogeneously distributed in all liver segments and therefore it is common to find discordance in SWE measurements. This issue becomes important in cirrhotic patients. In this situation, we suggest reporting the mean value of these measurements, in the condition that all have been obtained from different liver segments, following all the guidelines for SWE.

2. Conditions affecting STE measurements: SWE/STE measures stiffness, not the fibrotic content of the liver. Factors influencing liver stiffness which are independent of liver fibrosis:

- ❖ **Number of acquisitions:** Guidelines recommend obtaining 3 acquisitions and using their median value as representative of the stiffness. We suggest obtaining up to 5 acquisitions to better judge the variability between measurements by means of the interquartile range/median (IQR/M) ratio.

- ❖ **kPa vs. m/s:** It is recommended to use the default setting of the Resona 7 to perform measurements at 30 kPa E Scale. This way it is easier to identify a good quality area of the Shear Wave Elastogram.

- ❖ It is important to note that the SWE colors captured in the ROI are affected by using different E scale. However, the kPa stiffness measurement is not affected (**Fig.6 & Fig.7**).

- ❖ It is also recommended to use IQR/M as a quality factor: IQR/M should be $\leq 30\%$ when the median value is given in kPa and $\leq 15\%$ if the median value is given in m/s.

- ❖ **Difficult cases:** For difficult cases, the single frame SWE method STQ/HQE (Sound Touch Quantification High Quality Elastography) can be applied for stiffness quantification (**Fig. 8**).

- ❖ **Report:** Activate LSM box on the touch screen to auto transfer the measurement data to the LSM table report page (**Fig. 9 & Fig. 10**). The report page provides review and additional functions of the recorded STE and STQ stiffness data with IQR/M.

- ❖ **Cut-off values/CLD etiology and stage:** Knowledge of the etiology of the CLD of a specific patient (HBV, HCV, ALD, NASH) and the degree of necro-inflammation is a prerequisite, since different cut-off values apply per etiology and per grade of necro-inflammatory process.

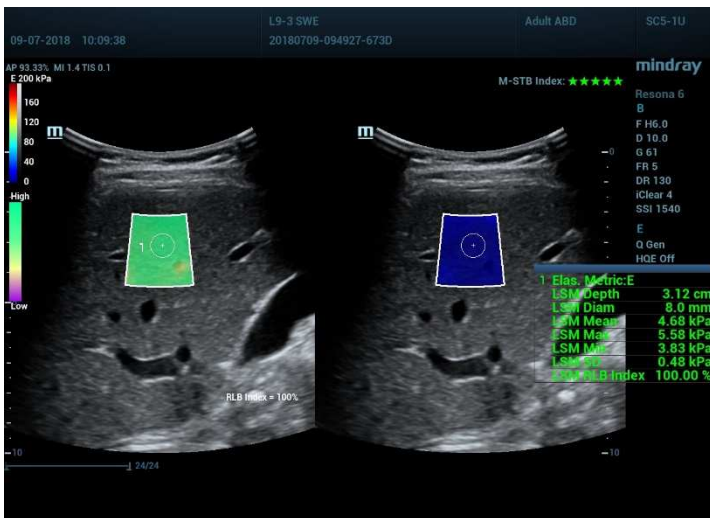


Fig. 6 Elastograms obtained in the same subject using an E scale of 200 kPa. The mean stiffness value is 4.68 kPa

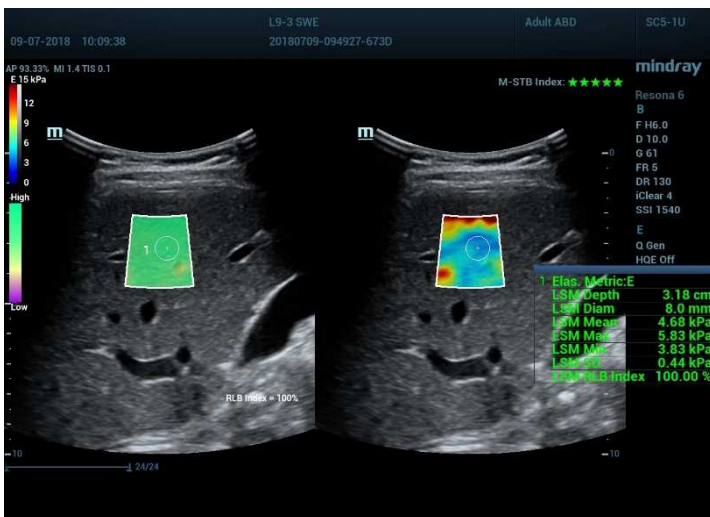

Fig. 7 Same patient, same ROI location and E scale setting of 15kPa. The stiffness value remains 4.68 kPa

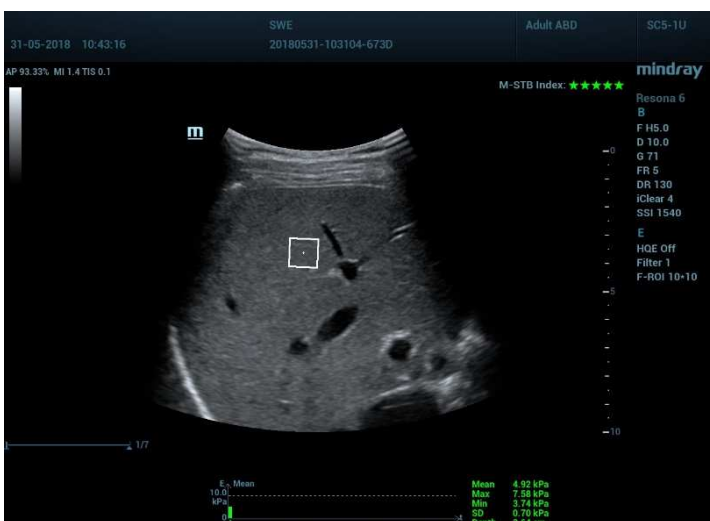


Fig. 8 Assessment of liver stiffness by STQ-HQE technique provides direct stiffness measurement within the ROI. This technique enables an instant kPa quantification calculation and can be useful for deeper lesions or patients only able to shortly hold their breath

a) Hepatic necro-inflammatory process is easily diagnosed through biochemical markers (ALT, AST, γ Gt). The extent of the necro-inflammatory activity influences SWE measurements, showing a steady increase of liver stiffness values.

b) Dilatation of the IVC and the HVs, often due to cardiac etiology, applies compression to the Liver parenchyma. B-Mode and CD can diagnose this clinical situation. In this case the STE measurement of the liver represents the sum of the endogenous liver stiffness and the externally exerted pressure from the IVC/HVs system. Different STE values are measured in the same liver segment in different phases of the cardiac cycle, due to the gradient of pressure in the HVs.

c) Important dilatation of the intra hepatic bile ducts, easily diagnosed through B-Mode images.

d) Dilated portal vein in portal hypertension. In this case liver stiffness measurements represent the sum of the endogenous liver stiffness due to fibrosis and the external compression applied to the liver by the dilated PV.

3. Spleen STE + Portal Hypertension

STE measurement of the spleen is feasible only in patients with splenomegaly ($L > 13$ cm). Normal STE measurement of the spleen is 13-16kPa.

Same directions of use and reliability apply both for the Liver and the Spleen: search for an intercostal space that has direct access to the splenic parenchyma and align the probe into it. Apply graded compression. Splenic stiffness of 25kPa or greater, corresponds to clinically significant portal hypertension (CSPH).

If liver stiffness is less than 20kPa and platelet count is more than 150G/l, varices needing treatment can be ruled out with high accuracy and endoscopy can be avoided.

In case of recent opening of portal collaterals/varices you may observe an abrupt fall of STE spleen measurement because of the reduction of the pressure inside the portal system.

4. Ascites

Ascites is not an obstacle for SWE measurements in the liver, as it is for Fibroscan. One condition applies: the probe-liver distance must be less than 6 cm. There is always a way to decrease the probe-liver distance by choosing an acoustic window through the LLL (Seg.IV) or changing the position of the patient (turning towards his left side) and therefore displacing a big amount of the ascitic fluid.

Name: DAN	DOB:	Gender: Unknown	Operator:
ID: 20180620-090033-673D	Age:	Ref.Physician:	
Height:	Weight:	BSA:	BMI:

STE-LSM	Depth(cm)	Diam(mm)	E Mean(kPa)	RLB Index	HQE	Calc
1	3.76	14.0	4.80	Off	Off	✓
2	3.67	14.0	4.82	Off	Off	✓
3	3.96	14.0	4.74	Off	Off	✓
4	3.94	14.0	4.76	Off	Off	✓
5	3.60	14.0	4.79	Off	Off	✓
6	3.98	14.0	4.71	Off	Off	✓
7	3.58	14.0	4.82	Off	Off	✓
8	3.96	14.0	4.72	Off	Off	✓
9	3.89	14.0	4.83	Off	Off	✓
10	3.80	14.0	4.75	Off	Off	✓

Overall Statistics						
	Median	IQR	IQR/Median	Average	STD	STD/Average
E Mean(kPa)	4.78	0.07	1.5%	4.78	0.04	0.9%

Fig. 9 The STE LSM Report displays the five acquisitions, their median values, the IQR, the IQR/M ratio, the average, the STD and the SD/Mean ratio. The median value should be considered indicative of liver stiffness. A measurement (in kPa) of good quality should have an IQR/Median \leq 30% when the median value is given in kPa and \leq 15% if the median value is given in m/s.

Name: DAN	DOB:	Gender: Unknown	Operator:
ID: 20180620-090033-673D	Age:	Ref.Physician:	
Height:	Weight:	BSA:	BMI:

STQ	Depth(cm)	Size(cmxcn)	E Mean(kPa)	HQE	Calc
1	4.56	1.0x1.2	8.91	On	✓
2	4.20	1.0x1.2	5.38	On	✓
3	4.20	1.0x1.2	5.38	On	✓
4	4.20	1.0x1.2	5.38	On	✓
5	4.20	1.0x1.2	5.38	On	✓

Overall Statistics						
	Median	IQR	IQR/Median	Average	STD	STD/Average
E Mean(kPa)	5.38	0.00	0.0%	6.09	1.41	23.2%

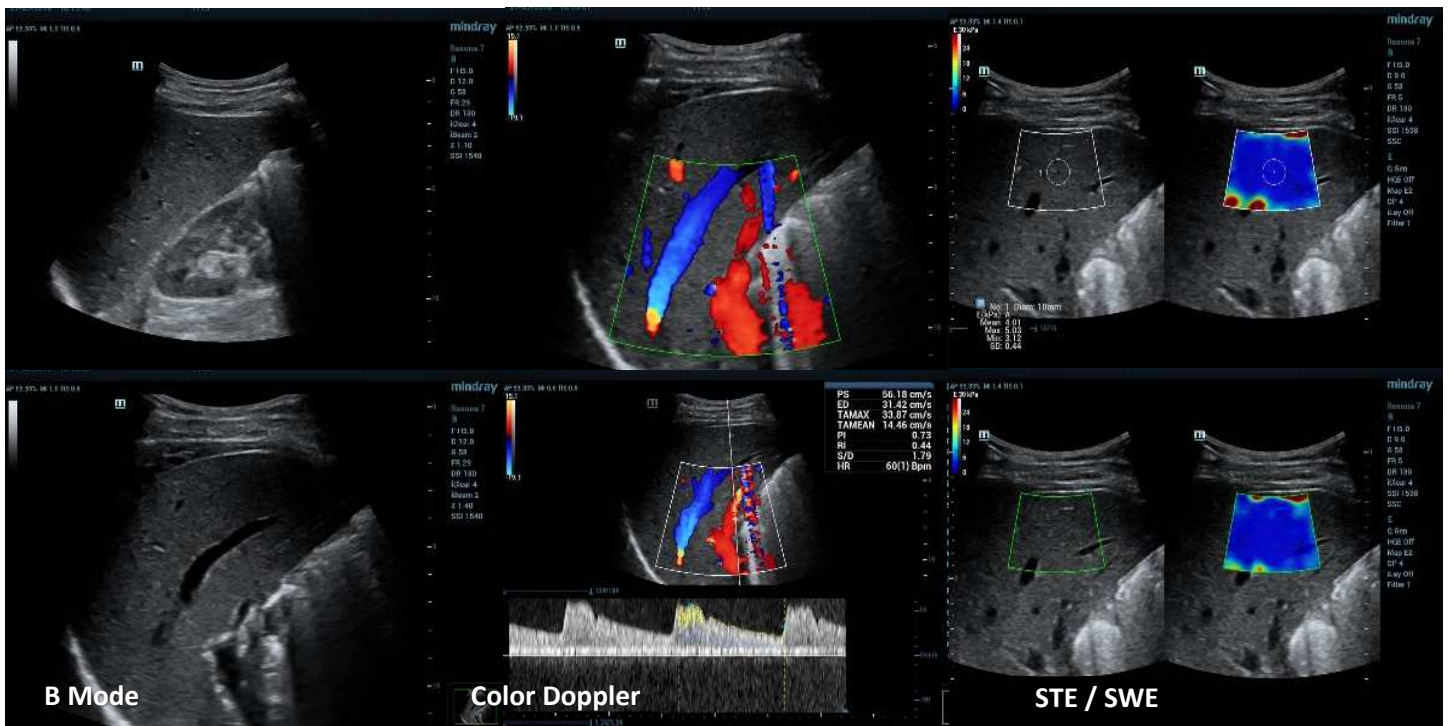
Fig. 10 Active the report box on the touch screen to auto transfer the measurement data to the table report page. The STQ LMS Report displays the IQR/M and SD/Mean ratios

Case Study I: Normal Liver

- Male, 35 years old, Epigastric pain. History of Infectious mononucleosis
- Biochemical markers: normal values of γ GT and aminotransferases
- Fibroscan: 4.3kPa / IQR:0.5

Ultrasound Examination Findings:

- US/STE performed in order to exclude liver fibrosis and steatosis
- US: Normal liver echostructure
- Color Doppler: normal hepatopetal and normal PW flow in the PV. Normal RI (0.44) of the Hepatic Artery
- STE: Homogenous blue color mapping in circular measurement area within the ROI box. Normal stiffness value of 4.01 kPa. Small red STE artifacts near the liver vessels are present



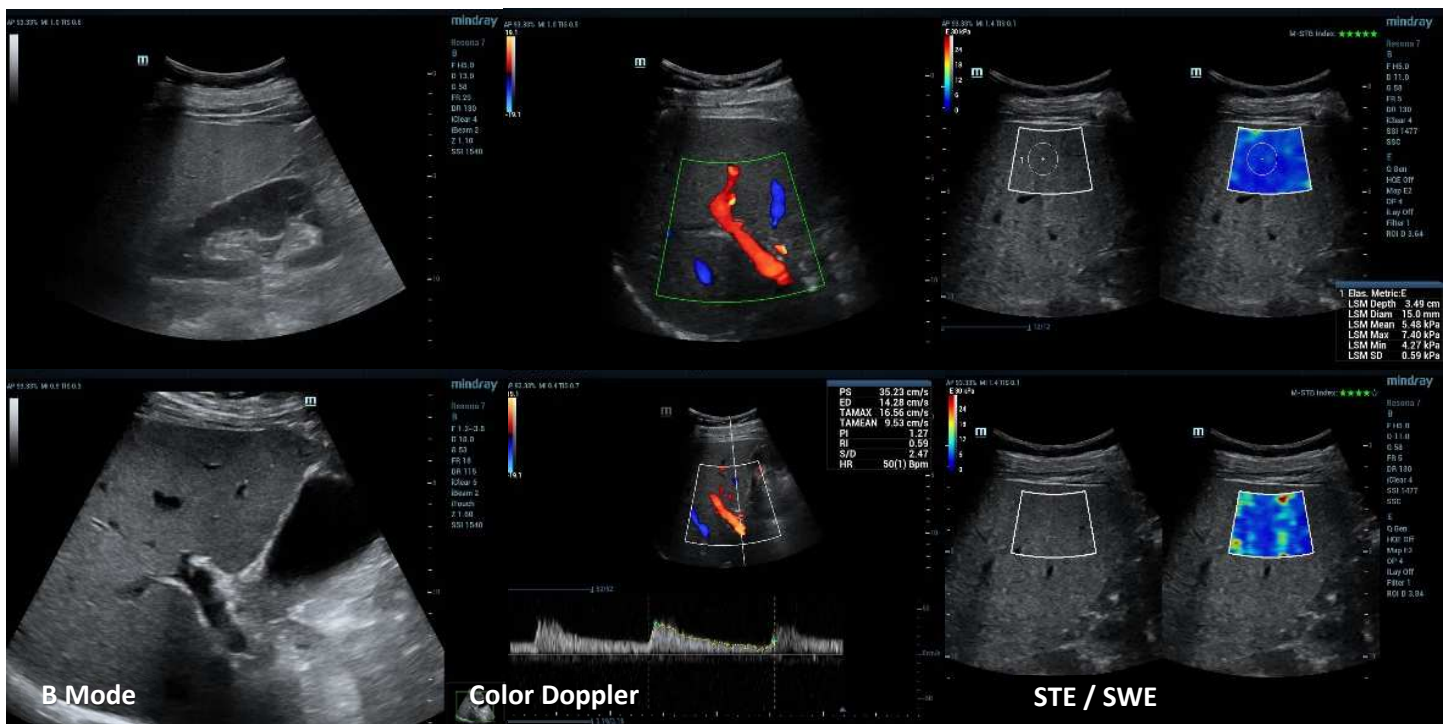
Conclusion / Practical Comment for Case Study I: Even in a “normal” appearing liver during the conventional B-Mode examination, use the STE/SWE in order to add the Elastography component of “normality”. Livers with normal echostructure may have pathologic Elastography values as a consequence of CLD. Every US liver examination should be completed with a STE/SWE examination.

Case Study II: Liver Fatty Infiltration

- Male, 35 years old, Obesity, Diabetes under insulin treatment
- Biochemical markers: Normal values. Small short-term augmentation of γ GT
- Fibroscan: 4,2 kPa, IQR: 1.2

Ultrasound Examination Findings:

- US/STE performed to exclude liver fibrosis and grade liver steatosis
- US: Augmentation of the liver echogenicity with hyperechoic and relatively hypoechoic regions due to focal fatty infiltration
- Color Doppler: There are no signs of portal hypertension (no dilatation of the PV, normal hepatopetal flow, normal RI of the Hepatic Artery)
- STE: mean value 5,48 kPa.
Despite the thick subcutaneous and perihepatic fat and the distance between the probe (skin) and the STE Box (>5cm), reliable STE liver quantification was achieved. The heterogeneity of STE signal is due to the partial distortion of the US beam while traversing the subcutaneous fat



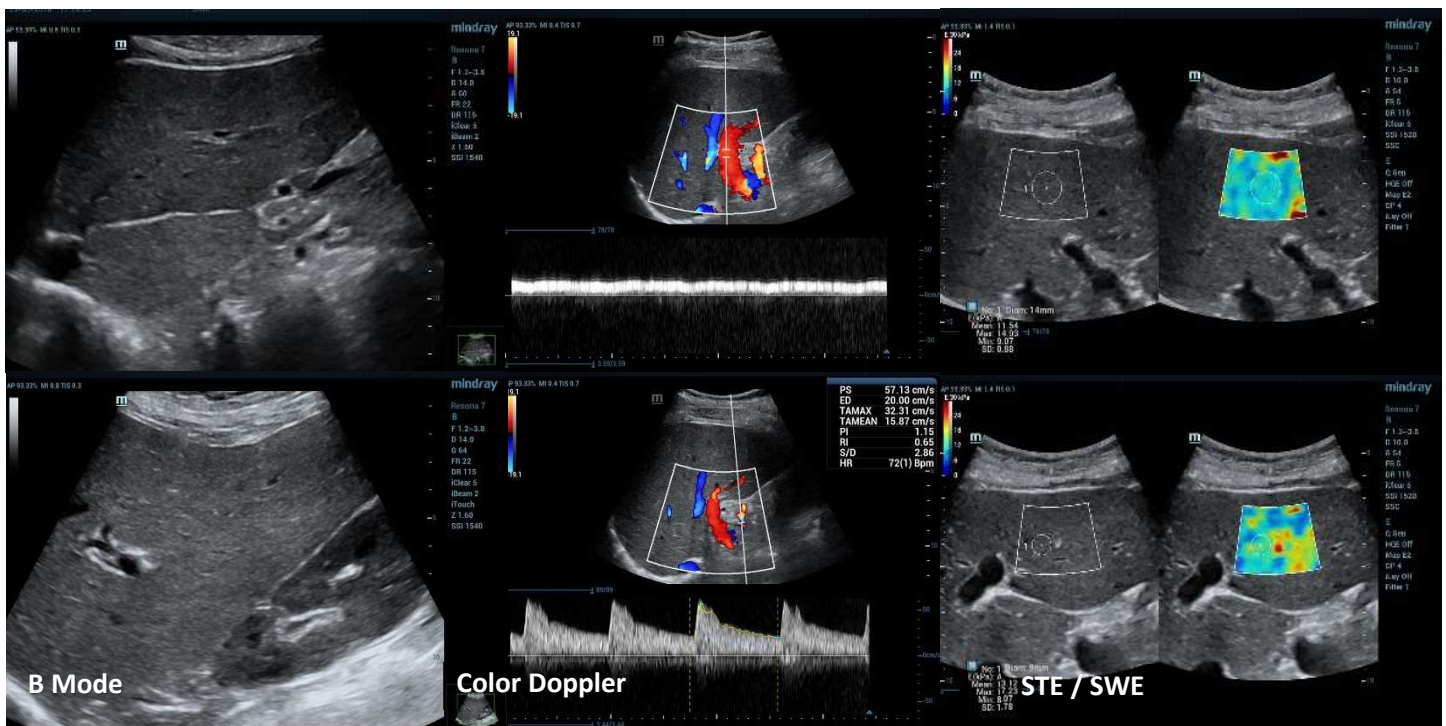
Conclusion / Practical Comment for Case Study II: Any liver with fatty infiltration is difficult to examine in all liver segments with B-Mode, CD and STE/SWE because the fatty component is attenuating the US beam. This is valid mainly for the subdiaphragmatic segments of the RLL. Use different acoustic windows, applying the probe in all accessible intercostal spaces for both B-Mode imaging and STE/SWE measurements. In the case of focal fatty infiltration, relatively hypoechoic regions correspond to normal liver parenchyma containing less fat than other neighboring segments. The hyperechoic and relatively hypoechoic liver segments show no difference in STE/SWE measurements because different tissue content in fat does not imply different STE measurement.

Case Study III: ALD

- Female 48 years old. Obesity, ALD, chronic alcohol abuse. Not drinking for 6 months
- Biochemical markers: γ GT: 223, AST: 137, ALT: 55
- Pathology: F2 Metavir score, Steatosis grading 2, necro-inflammatory process grading 9
- Fibroscan: 10,6 kPa IQR: 1.7

Ultrasound Examination Findings:

- US/STE performed in order to grade liver Fibrosis
- US: Hepatomegaly and important hypertrophy of the left and the caudate lobe
- Color Doppler: There are no signs of portal hypertension (normal diameters and hemodynamics of the PV, HVs and HA)
- STE: mean value of 11.54 kPa
- Reliable STE measurements are obtained in both the RLL and LLL. The augmented volume of the LLL offers an alternative acoustical window. The immobility of the LLL (no transmission of heart movements) is a prerequisite for a reliable STE measurement



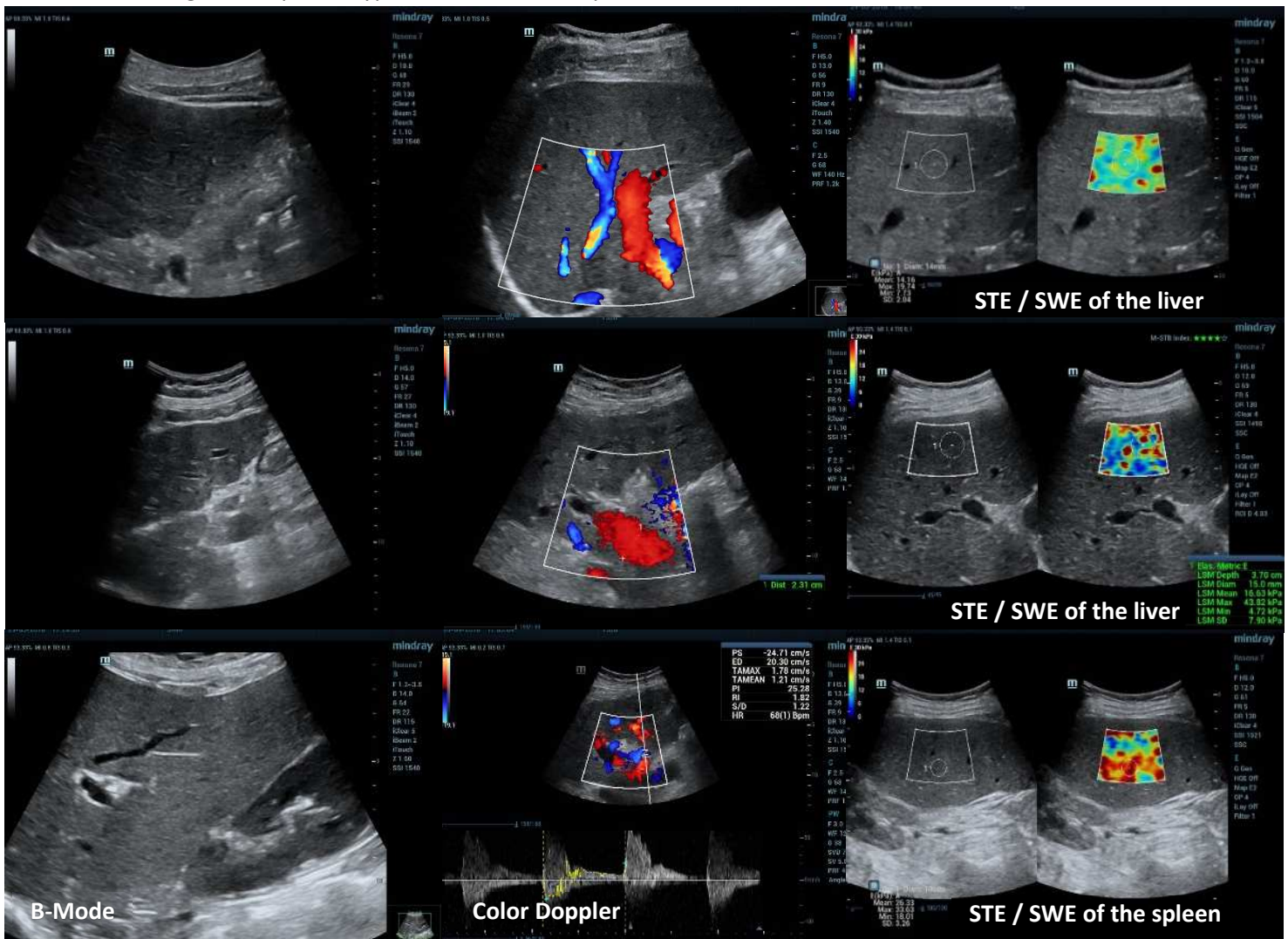
Conclusion / Practical Comment for Case Study III: In patients with ALD, liver fatty infiltration and fibrosis often co-exist. Progressing towards cirrhosis the fibrotic component prevails. During the long run of CLD due to ALD the necro-inflammatory process also alters the echostructure and the STE/SWE measurements. Be aware that possible “active” necro-inflammatory process of any cause increases STE/SWE values.

Case Study IV: Cirrhosis and Portal Hypertension

- Female, 56 years old, CHC Cirrhosis and Portal Hypertension
- Biochemical markers: small fluctuation of aminotransferases during the last year
- Pathology: Had had Liver Biopsy 8 months before the STE examination. Severe fibrosis (F4), non-significant Necro-inflammatory process, no steatosis
- Endoscopy: small (grade I) varices in the fundus of the stomach
- Fibroscan: 15.04 kPa, IQR: 3.3

Ultrasound Examination Findings:

- US/STE performed in order to grade liver Fibrosis, exclude HCC, grade Portal Hypertension and estimate the risk of hemorrhage due to varices
- US: Liver cirrhosis with hypertrophy of the LLL and the CL and splenomegaly. Liver lobulations on the proximal and distal surface of the LLL represent regenerating nodules. Lobulations along the hepatic vein are also observed. The B-Mode image alone is sufficient for diagnosing cirrhosis.
- Color Doppler: Portal Hypertension with dilatation of the PV which preserves slow hepatopetal flow. Pathological Hepatic Artery RI indicating clinically significant Portal Hypertension (hepatic artery RI: 1.12)
- STE: Liver mean value 16.63 kPa. Spleen mean value 32.52 kPa. The spleen Elastography converges with other morphological and hemodynamic features of portal hypertension, meaning clinically significant portal hypertension. Normal spleen STE values 14-17 kPa



Conclusion / Practical Comment for Case Study IV: In livers with CLD always perform a B-Mode examination both with a convex and a suitable linear (L9-3U) probe in order to exclude or confirm the existence of lobulations on the liver's surface or on the wall of the HV's.

Use B-Mode and CD to measure PV and HA diameters and longitudinal diameter of the spleen as valid signs of PH. Exclude the presence of ascites in the pelvis.

Finally, perform both STE/SWE of the liver and the spleen for estimating liver fibrosis and for adding an Elastographic argument (Spleen STE/SWE) of PH.

References:

1. Dietrich CF, Bamber J, Berzigotti A, Bota S, Cantisani V, Castera L, Cosgrove D, Ferraioli G, Friedrich-Rust M, Gilja OH, Goertz RS, Karlas T, de Knecht R, de Ledingham V, Piscaglia F, Procopet B, Saftoiu A, Sidhu PS, Sporea I, Thiele M.

EFSUMB Guidelines and Recommendations on the Clinical Use of Liver Ultrasound Elastography, Update 2017 (Long Version). *Ultraschall Med* 2017;38:e16-e47

2. Ferraioli G, Filice C, Castera L, Choi BI, Sporea I, Wilson SR, Cosgrove D, Dietrich CF, Amy D, Bamber JC, Barr R, Chou YH, Ding H, Farrokh A, Friedrich-Rust M, Hall TJ, Nakashima K, Nightingale KR, Palmeri ML, Schafer F, Shiina T, Suzuki S, Kudo M.

WFUMB guidelines and recommendations for clinical use of ultrasound elastography: Part 3: liver. *Ultrasound Med Biol* 2015;41:1161-79

3. Barr RG, Ferraioli G, Palmeri ML, Goodman ZD, Garcia-Tsao G, Rubin J, Garra B, Myers RP, Wilson SR, Rubens D, Levine D.

Elastography Assessment of Liver Fibrosis: Society of Radiologists in Ultrasound Consensus Conference Statement. *Radiology* 2015;276(3):845-6

4. European Association for Study of L, Asociacion Latinoamericana para el Estudio del H. EASL-ALEH Clinical Practice Guidelines: Non-invasive tests for evaluation of liver disease severity and prognosis. *J Hepatol* 2015; 63: 237–264

5. Tsochatzis EA, Gurusamy KS, Ntaoula S et al. Elastography for the diagnosis of severity of fibrosis in chronic liver disease: a meta-analysis